

PATIENT

Spike Delogios

SPECIES

Canine

BREED

Doberman

SEX

Male

AGE

2024

WEIGHT

64lbs

INTERPRETED BY

Maggie Machen Lamy,
 DVM, DACVIM
 (Cardiology)

IMAGING PERFORMED BY

Rebekah Jakum, CVT,
 ARDMS/RVT

HOSPITAL NAME

Community VP

REFERRING VET

Dr. Carpenter

INVOICE

45835

DATE

11/19/25

PRESENTING CLINICAL SIGNS

History: Breed screen exam.

ECHOCARDIOGRAM FINDINGS

2D, m-mode, color flow and doppler imaging is available. Normal mitral valve with no obvious prolapse into the left atrial lumen. No mitral regurgitation with normal left atrial dimension. Normal LV diameter with adequate myocardial function. Normal LV wall thickness. The tricuspid valve is normal with no TR. Normal right atrial and ventricular diameter and morphology indicating no overt evidence of pulmonary arterial hypertension. The pulmonic and aortic valves are normal in morphology and mobility. Normal aortic outflow velocities; laminar flow. Normal pulmonary outflow velocity with no pulmonic insufficiency. No pericardial or pleural effusion noted.

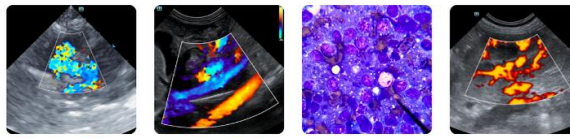
CARDIAC CHART

CANINE CARDIAC PARAMETERS	MR VMAX (m/s)	TR VMAX (m/s)	LA/AO (Boon method)	LA/AO (Heart Base; Swe)	FS (%)	EF (%)	EPSS (cm)
NORMAL PARAMETER	4.5-5.5	<2.7	1.3	<1.6	28-40	40-100	<0.6
PATIENT	NA	NA	NM	1.2	30	58	NM
CANINE CARDIAC PARAMETERS	HR (BPM)	AV VMAX (m/s)	PV MAX (m/s)	BODY WEIGHT (kg)	LA 2D short axis Base view (cm)	LVIDd Avg; 2D and m-mode short axis (cm)	LVIDs Avg; 2D and m-mode short axis (cm)
NORMAL PARAMETER	50-100	0.7-1.7	0.7-1.6	BELOW	BELOW	BELOW	BELOW
PATIENT		1.8	1.1	29.0	2.8	4.2	2.9
*Normal chamber parameters expressed as a mean value				3	1.27 (5.3)	2.46 (2.46)	1.36 (5.5)
BODY WEIGHT DEPENDENT PARAMETERS				5	1.40 (4.5)	2.74 (5.2)	1.60 (4.7)
Adapted from June Boon, Veterinary Echocardiography, 1998 Rishniw M and Hollis NE, J Vet Intern Med 2000; 14:429-435 Hansson et al, Vet Rad and Ultrasound 2002 Bonagura et al. Echocardiography: principles of interpretation, Vet Clin North Am 15:1177, 1995				10	1.50 (3.8)	3.27 (3.5)	2.06 (3.1)
				15	1.83 (2.0)	3.71 (2.4)	2.43 (2.1)
				20	2.02 (1.9)	4.14 (2.2)	2.80 (2.0)
				25	2.18 (2.4)	4.48 (2.9)	3.10 (2.5)
				30	2.33 (3.3)	4.83 (3.9)	3.39 (3.4)
				35	2.48 (4.3)	5.17 (5.0)	3.69 (4.5)
				40	2.62 (5.2)	5.48 (6.1)	3.96 (5.4)
				50	2.88 (7.1)	6.07 (8.3)	4.46 (7.4)

INTERPRETATION OF THE FINDINGS & FURTHER RECOMMENDATIONS

The cardiac structure and function in this patient are overtly normal, with no evidence of occult DCM or chronic valve disease. The function is reasonable for this signalment, and no significant valvular issues, structural changes or arrhythmias are readily apparent.

In this signalment, recheck echocardiograms are recommended every 6-12 months. Additionally, holter monitoring every 6-12 months should also be considered to screen for the arrhythmic



PATIENT

Spike Delogios

SPECIES

Canine

BREED

Doberman

SEX

Male

AGE

2024

WEIGHT

64lbs

INTERPRETED BY

Maggie Machen Lamy,
DVM, DACVIM
(Cardiology)

IMAGING PERFORMED BY

Rebekah Jakum, CVT,
ARDMS/RVT

HOSPITAL NAME

Community VP

REFERRING VET

Dr. Carpenter

INVOICE

45835

DATE

11/19/25

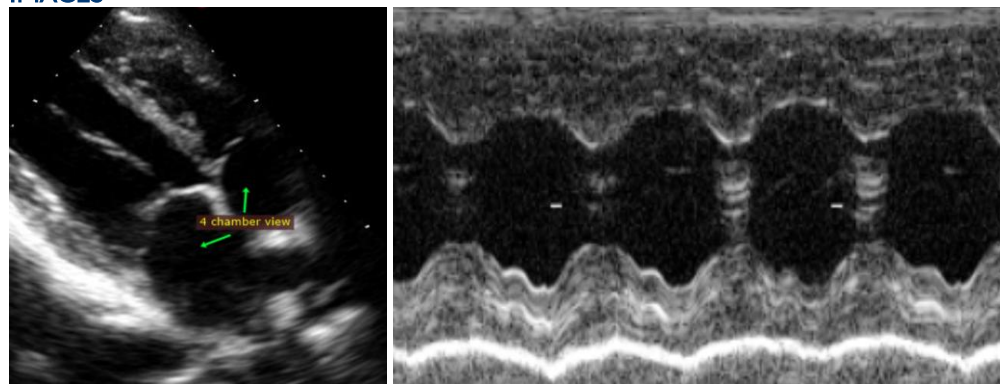
form of disease. Finally, the BNP test has also been shown to be a decent predictor of occult DCM and can consider routine screening going forward.

No cardiac medications are indicated at this time. Monitor for development of a cough, labored breathing, exercise intolerance or collapse episodes. I generally recommend fish oil supplementation in any Doberman, given the anti-arrhythmic properties of omega fatty acids.

No cardiac contraindication for general anesthesia.

Recheck annually, sooner if clinical signs or a heart murmur arises.

IMAGES



The information and recommendations provided are based on the images presented by the referring veterinarian. No evaluation can be communicated regarding pathology that was not visible in the image/video clips provided.

Thank you for this referral. This report was generated using transcription software, and minor dictation errors may be present. If the clinical or image interpretation does not parallel your findings or if I can be of any further assistance, please contact me.

Maggie Machen Lamy, DVM
Diplomate of the American College of Veterinary Internal Medicine (Cardiology)
info@sonopath.com